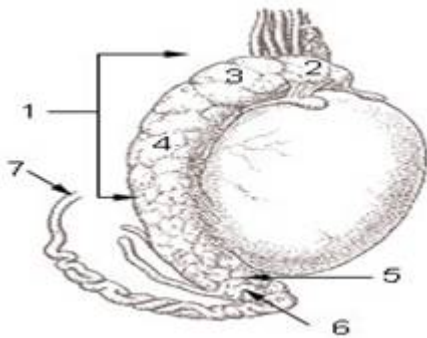


Human Male Internal Genital Organs

Created: Thursday, 12 May 2011 08:43 | Published: Wednesday, 11 May 2011 00:00 | Written by [Super User](#) | [Print](#)

What are the Internal Genetal organs of Human Male?



Epididymis

It is a part of the male [reproductive system](#) and is present in all male amniotes. It is a narrow, tightly-coiled tube connecting the efferent ducts from the rear of each testicle to its [vas deferens](#).

1. Epididymis
2. Head of epididymis
3. Lobules of epididymis
4. Body of epididymis
5. Tail of epididymis
6. Duct of epididymis
7. Deferent duct ([vas deferens](#))

Regions of Epididymis:

The epididymis can be divided into three main regions

The head

- Known as Caput
- Receives [spermatozoa](#) via the [efferent ducts](#) of the [mediastinum](#) of the [testis](#).
- It has a thin [myoepithelium](#).
- Has dilute sperm

The body

- Known as Corpus

The tail

- Known as Cauda.
- It has a thicker myoepithelium
- Has concentrated sperm.

Histology of epididymis

- Covered by a [pseudostratified epithelium](#) composed of short basal cells and tall principal cells with non-motile [stereocilia](#).
- Basement separated the [epithelium](#) from the [connective tissue](#) wall.

Role in storage of sperm and ejaculant

During [ejaculation](#), sperm flow from the lower portion of the epididymis. Here sperms are in inactive mode and can't able to swim. They transported to the [vas deferens](#), and are mixed with the diluting fluids of the [seminal vesicles](#) and other accessory glands prior to ejaculation. This is known as formation of [semen](#).

Spermatogenesis

Sperm production begins at puberty at continues throughout life. Millions of sperms are being produced each day.

After the formation it moves into the epididymis get matured mature and are stored.

Male Sex Hormones:

- [Follicle-stimulating hormone \(FSH\)](#)
- [Luteinizing hormone \(LH\)](#).

LH is controlled by the GnRH. LH stimulates cells in the seminiferous tubules to secrete [testosterone](#). This hormone plays an important role in sperm production and it helps to develop male secondary sex characteristics.

FSH help in sperm maturation. Negative feedback by testosterone controls the actions of GnRH.

Sexual Structures

- Sperm pass through the [vas deferens](#)
- Vas deference connects to the [urethra](#) through a ejaculatory duct.
- The urethra passes through the penis and opens to the outside.
- Secretions from the seminal vesicles add fructose and prostaglandins to sperm as they pass.
- The prostate gland secretes a milky alkaline fluid.
- The bulbourethral gland secretes a mucus-like fluid that provides lubrication for intercourse.
- Sperm and secretions make up semen.

Want to know more about male internal genital Organs'? [Click here](#) to schedule live homework help from a certified tutor!

About eAge Tutoring

[eAgeTutor.com](#) is the premium online tutoring provider. Using materials developed by highly qualified educators and leading content developers, a team of top-notch software experts, and a group of passionate educators, eAgeTutor works to ensure the success and satisfaction of all of its students.

[Contact us](#) today to learn more about our guaranteed results and discuss how we can help make the dreams of the student in your life come true!

Reference Links:

- <http://en.wikipedia.org/wiki/Epididymis>
- [http://www.cartage.org.lb/en/themes/sciences/lifescience/generalbiology/physiology/ReproductiveSystem/HumanReproduction/HumanReproduction/HumanReproduction.htm](http://www.cartage.org.lb/en/themes/sciences/lifescience/generalbiology/physiology/ReproductiveSystem/HumanReproduction/HumanReproduction.htm)
- http://society.indianetzone.com/pregnancy/1/reproductive_anatomy.htm
- <http://www.youtube.com/watch?v=POpbN6RHOO0>
- <http://www.youtube.com/watch?v=AsXjFRa4tUQ&NR=1>

Category:ROOT

[Joomla SEF URLs by Artio](#)